

A 39-Years-Old Female with Left Anterior Epistaxis: Case Report

Irene Oktavia Anggraini^{1*}, Halim Gumelar¹, Iwan Setiawan Adji²

¹ Faculty of Medicine, Universitas Muhammadiyah Surakarta, Surakarta, Indonesia

²Departement of ENT-HN, RSUD Karanganyar, Jl.Yos Sudarso Karanganyar, 495118, Central Java, Indonesia

Abstract

Purpose: The purpose of this report is to present a case of a left anterior epistaxis in a 39-years-old female, analyze its etiology, risk factors, clinical symptoms, diagnostic examinations, and the treatment provided. This report also highlights the importance of prevention and proper management to improve patient prognosis.

Methodology: The methodology used in this report is a clinical case study. Data were collected through anamnesis, physical examination, and supporting examinations such as CT scan and histopathology. The patient's management was analyzed based on existing medical theories and appropriate treatment was provided according to the patient's condition.

Results: The patient was diagnosed with a left maxillary abscess, presenting with persistent pain and swelling in the left cheek for two months. CT scan findings suggested left-sided sinusitis with a possible abscess, while histopathology confirmed chronic sinusitis. The patient received antibiotic therapy (Ceftriaxone and Metronidazole), symptomatic treatment (Santagesic, Methylprednisolone, and Ranitidine), and education on oral hygiene and follow-up care. The patient had a history of left maxillary surgery and smoking habits, both of which were identified as significant risk factors for developing the condition.

Applications/Originality/Value: This report provides insights into the importance of early diagnosis and proper management in maxillary abscess cases. The findings can be useful for healthcare professionals to understand clinical signs and effective treatment approaches for similar cases. The study emphasizes the need for preventive measures, such as maintaining good oral hygiene and avoiding risk factors like smoking.

Introduction

Bleeding is the release of blood from blood vessels which can occur due to various causes such as injury, systemic disease or disorders of blood clotting. Bleeding from inside the nose is called epistaxis. Epistaxis is often a symptom or manifestation of a common disease and can be experienced by individuals of all ages. Although often mild, epistaxis can be caused by local abnormalities or systemic abnormalities. Local abnormalities include trauma, anatomical abnormalities, blood vessel abnormalities, local infections, foreign objects, and the influence of environmental air. Systemic disorders such as cardiovascular disease, blood disorders, systemic infections, changes in atmospheric pressure, hormonal disorders and congenital abnormalities (Fishman J et al, 2018).

Based on the location of the bleeding, epistaxis is divided into two, namely anterior and posterior epistaxis. Anterior epistaxis is the most common type, where bleeding originates from the anterior septum or anterior ethmoidal artery, precisely in the area known as Kiesselbach's plexus. This area is a highly vascularized spot, making it susceptible to bleeding due to minor trauma, irritation, or certain medical conditions. Bleeding in the anterior septum is usually mild, such as dry air, a habit of picking the nose and mostly occurs in children, often recurs and can stop on its own. Posterior epistaxis is bleeding that originates from the back of the nasal cavity, usually from branches of the sphenopalatine artery or posterior ethmoidal artery which are located deeper in the nose. More common in adults, especially those who are elderly or have underlying medical conditions, such as hypertension, atherosclerosis, or blood clotting disorders due to rupture of the sphenopalatine artery. This condition is often more severe because blood can

* Corresponding author: ireneoktaviaa@gmail.com

flow backward into the throat, making it difficult to detect quickly and potentially causing serious complications, such as aspiration or anemia (Send T et al, 2021).

Epistaxis is rarely found in infants, often in children, young adults, and more often in older adults. Epistaxis or nose bleeding is reported to occur in 60% of the general population. The peak incidence of epistaxis was found to occur at ages <10 years and >50 years. Anterior epistaxis occurs more often in children and young adults, while posterior epistaxis occurs more often in older people, especially in men aged >50 years with hypertension. The problem in this case is that anterior epistaxis is found in adult female patients, whereas anterior epistaxis occurs more often in children.

Case description

A 39 years old woman came to the emergency room at Karanganyar Regional Hospital on Tuesday, September 24 2024 with complaints of bleeding from the left side of her nose. There was blood coming out of the left side of the nose since this morning at 07.00 WIB, the blood came out continuously, only a little about 5 cc for 5 minutes and stopped. In the afternoon at 18.15 WIB blood came out of the left nose again, the blood came out continuously at around 20 cc for 15 minutes and then stopped. After that, the patient immediately went for treatment to the nearest clinic and when he arrived at the clinic the patient again complained of bleeding from the left nose as much as 10 cc with a blood pressure of 217/140mmHg and was referred to Karanganyar Regional Hospital. There were no complaints in the throat, ears and head-neck area. Systemic complaints, namely patients complain that their stomach feels tight and their chest feels tight.

Past medical history the patient admitted that he had a history of vertigo about 5 years ago. History of recognized and uncontrolled hypertension. Denied history of diabetes mellitus. Family history of disease, namely hypertension in the patient's mother. From the results of the physical examination, the patient's vital signs were: blood pressure (BP) 212/138mmHg, body temperature 36.7oC, pulse (HR) 121x/minute, respiratory rate (RR) 22x/minute, oxygen saturation (SpO2) 99% free air. The patient's general condition is moderate, consciousness E4M6V5 compos mentis. On examination the local status of the nose, ears, throat and head and neck were within normal limits. In this patient, an anterior tampon was placed to stop the bleeding. Then for therapy they were injection and tablet oral: infus RL 20 tpm, inj. Tranexamat Acid 250mg/8h, inj. Omeprazole 40mg/12h, and inj. Furosemide 1amp (Extra, just one time). The ENT specialist provides advice, namely joint treatment with an internal medicine doctor. From an internal medicine doctor added some hypertension medication, they were: captopril 25 mg three times a day, amlodipine 10mg once a day, and herbesser CD 200mg once a day. On the next day, the patient was feeling a little bit better, but for the bleeding was still continued and the blood pressure still high so an internal medicine doctor added a new medication, it was adalat oros once a day to decreased the blood pressure. Next day, the patient was feeling better, the bleeding stopped and blood pressure was normal. Advice from the ENT specialist doctor was tampon removal and the patient could went home.

Discussion

Definition

Epistaxis (nosebleed) is one of the most common ear, nose, and throat emergencies within the emergency office or the primary care clinic. There are 2 sorts of nosebleeds: anterior (more common) and posterior (less common but more likely to require medical consideration). The source of 90% of anterior nosebleeds is inside Kiesselbach plexus (moreover known as Little's area) on the anterior nasal septum. There are 5 named vessels whose terminal branches supply the nasal cavity (Fishman J et al, 2018).

Anatomy

The nasal mucosa could be a dynamic structure with a rich vascular supply. The arterial supply is from the inner and external carotid arteries, with anastomoses between the two systems inside the nasal mucosa. The arteries pass inside the mucoperiosteum and mucoperichondrium, with the special case of branches passing along the bony canals within the inferior and middle turbinates (Lambardo et al, 2016).

External carotid system

Arterial blood flows from the external carotid artery to the maxillary supply route and after that the sphenoid artery (SPA) some time recently entering the posterior part of the nose through the sphenoid foramen. It brings the

biggest supply of arterial blood to the nose. The sphenoid foramen itself is found at the posterior end of the middle tube. Anteriorly, blood flows along the facial artery to the superior labial artery before entering the anterior part of the nose (Sowerby et al, 2021).

Internal carotid artery blood flows along the ophthalmic artery through the superior orbital fissure to the orbital apex, at that point anteriorly to drain the anterior and posterior ethmoid arteries (Figure 1) from the cribriform plate. Inside the cranial cavity, the two arteries branch, giving rise to terminal branches that supply the dura of the anterior fossa; a few branches run inferiorly to supply the superior nasal cavity. The anterior ethmoid artery is the bigger and most constant of the two; the posterior ethmoid artery may be missing in up to 30% (Sowerby et al, 2021).

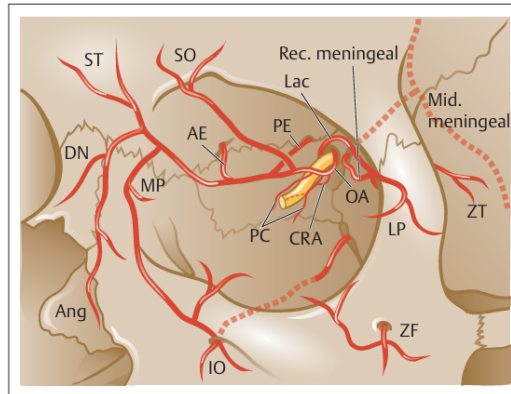


Figure 1. Vascular branches of the internal carotid artery system.

Vascular anastomosis

The mucosa of the anterior nasal septum is provided by arterial blood from the septal branch of the SPA, the more prominent palatine artery by means of the incisive canal, the superior labial artery, and the branch of the anterior ethmoidal superior artery (Sowerby et al, 2021).

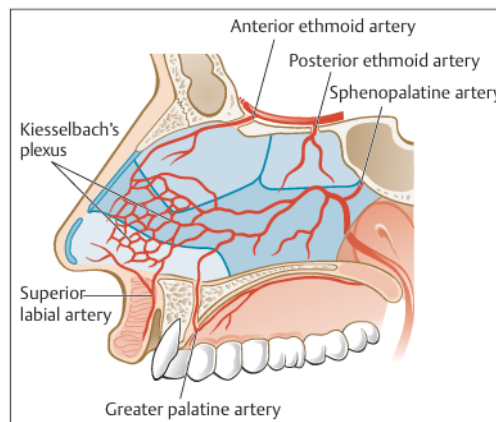


Figure 2. Anastomosis of blood vessels in the nasal septum.

Etiology

Epistaxis can be categorized as primary (idiopathic) or secondary (due to an identifiable cause). It is estimated that 70% of bleeding is primary bleeding. It is also useful to consider local (in the nose) or systemic etiological factors (Send T et al, 2021).

Primary Spontaneous Epistaxis

Primary epistaxis alludes to spontaneous idiopathic bleeding from the nose. The reasons why this happens are not completely caught on. In any case, we are able to hypothesize that in more seasoned people, the nasal mucosa and blood vessels ended up more delicate and more vulnerable to spontaneous bleeding. Spontaneous mucosal bleeding from the front nasal septum happens regularly in all age bunches, particularly in children. These mucosal areas are susceptible to advanced trauma, as well as being susceptible to drying up and exposure to irritants, but without direct prove of a conclusive cause, these bleedings are considered idiopathic (Send T et al, 2021).

Secondary Epistaxis

In case the bleeding is caused by a known cause, it is called secondary epistaxis. There are numerous causes of secondary epistaxis, but most are post-traumatic or secondary to sino nasal surgery. Any clutter that disturbs the normal healthy mucosa can cause nosebleeds; conditions incorporate sinonasal tumors, granulomatous infection, septal perforation/ulceration, and exposure to environmental/occupational irritants (Send T et al, 2021).

Other causes

Apart from the causes described above, there may be other causes may occur, namely:

First, Deviated septum, can cause mucosal drying and atrophy and is regularly related as a cause of epistaxis in clinical hone.

Second, Coagulation clutters, the foremost common predisposing components for epistaxis are the use of ibuprofen and nonsteroidal anti-inflammatory drugs (NSAIDs), which are frequently used as self-treatment. This bunch of drugs influences platelet work. Clopidogrel, which is prescribed for patients intolerant to ibuprofen or as an adjunct to ibuprofen within the management of cardiovascular illness, is additionally a strong antiplatelet drug.

Third, Hypertension is frequently said as a cause of epistaxis, but a cause-and-effect relationship has not been demonstrated. In spite of the fact that it is widely believed that there's a connect between hypertension and epistaxis, this remains controversial: both conditions are common, and both are common in more seasoned individuals. What is clear is that not everybody who endures from hypertension will involvement epistaxis. Hypertension is regularly thought to be more likely to draw out the duration of spontaneous epistaxis, but not one or the other this nor the generally relationship between epistaxis in grown-ups and hypertension has been recognized.

Fourth, Alcohol consumption and liver disease has described a relationship between alcohol consumption and epistaxis, which may be a result of alcohol-induced platelet dysfunction. Alcohol was watched to cause prolongation of bleeding time, indeed at low levels of alcohol consumption, specifically between 1 and 10 units per week. Liver disease ought to moreover be considered, as this will affect coagulation not as it were by decreasing the production of most coagulation components, but will too affect the clearance of activation products. Vitamin K-dependent components (prothrombin; components VII, IX, and X; proteins C and S) may be decreased in acute or persistent hepatocellular infection. Liver failure and cirrhosis can happen with the whole range of factor lacks when all procoagulant and inhibitory factors are decreased. Typically a reflection of disabled protein synthesis (Send T et al, 2021).

Risk factors

Little's area, or Kiesselbach area, is especially at risk of epistaxis since it is an area within the nasal septum that's rich in blood vessels. There are a few main reasons why this area is inclined to nosebleeds:

Thick arrange of blood vessels

Little's area has numerous little connected blood vessels, including branches of the anterior ethmoidal artery, sphenopalatine artery, superior labial artery, and more prominent palatine artery. The thickness of these blood vessels makes them susceptible to rupture, indeed with negligible injury (Tabassam, 2022).

Superficial area

The blood vessels in Little's area are found very near to the surface of the nasal mucosa, so they are effortlessly damaged due to minor trauma such as picking the nose, breathing out as well mightily, or when the air is dry (Tabassam, 2022).

Presentation to the environment

This front part of the nose is more regularly uncovered to natural changes such as dry air, cold, or clean irritation, which can cause irritation and dry out the mucosa, expanding the risk of blood vessel rupture (Tabassam, 2022)

Low humidity

Dry air can cause the nasal mucosa to dry out and gotten to be brittle, making it less demanding to bleed when there's friction or minor trauma. These factors make Little's area one of the most common locations for anterior nosebleeds, which are usually simpler to control than back nosebleeds. nosebleeds, which are usually easier to control than posterior nosebleeds (Tabassam, 2022).

Conclusion

From what we have discussed, anterior epistaxis can occur in adults especially in this patient. This patient caused was hypertension. This was explained in the research of (Byun H et al,2021) they said that patients with hypertension had an increased risk of epistaxis requiring hospital visits. In addition, epistaxis in patients with hypertension appeared to need more emergency department visits and require more posterior nasal packing procedures compared with patients without hypertension. Medical counseling about epistaxis is advisable for individuals with hypertension, and the presence of hypertension should be considered in managing nasal bleedings.

Conflict of Interest

Anterior epistaxis usually happen in children but in this case can happen too in adult. In this patient, anterior epistaxis happen because of she had hypertension.

Acknowledgement

We convey our deepest thanks to Dr.dr.H.Iwan Setiawan Adji, Sp. THT-KL for providing very meaningful guidance, advice and resources in the process of this publication.

References

1. Fishman J, Fisher E, Hussain M. Epistaxis audit revisited. *J Laryngol Otol.* 2018 Dec;132(12):1045.
2. Send T, Bertlich M, Eichhorn KW, Ganschow R, Schafigh D, Horlbeck F, Bootz F, Jakob M. Etiology, Management, and Outcome of Pediatric Epistaxis. *Pediatr Emerg Care.* 2021 Sep 01;37(9):466-470.
3. Lombardo GA, Tamburino S, Tracia L, Tarico MS, Perrotta RE. Lateral Nasal Artery Perforator Flaps: Anatomic Study and Clinical Applications. *Arch Plast Surg.* 2016
4. Tabassom A, Cho JJ. Epistaxis Stat Pearls. *StatPearls.* 2022.
5. Sowerby L, Rajakumar C, Davis M, et al. Epistaxis first-aid management: a needs assessment among healthcare providers. *J Otolaryngol Head Neck Surg.* 2021; 50: 7.
6. Byun, H., Chung, J.H., Lee, S.H., Ryu, J., Kim, C. and Shin, J.H., 2021. Association of hypertension with the risk and severity of epistaxis. *JAMA Otolaryngology-Head & Neck Surgery*, 147(1), pp.34-40.